



PATIENT

Rookie Morrissey

SPECIES

Canine

BREED

Doberman Pinscher

SEX

Male Neutered

AGE

9 years

WEIGHT

42kgs

INTERPRETED BY

Maggie Machen Lamy,
DVM, DACVIM
(Cardiology)

IMAGING PERFORMED BY

Nigel Gumley, DVM

HOSPITAL NAME

Cedarview Animal
Hospital

REFERRING VET

Dr. Gumley

INVOICE

22313

DATE

12/7/21

PRESENTING CLINICAL SIGNS

History: Recheck echo. Asymptomatic.

-Current medications: Pimobendan 10mg BID; thyroxine 0.6mg BID,

-Blood pressure: 155/70 (110), 135/70 (95) and 110/90 (95)mmHg.

-Pertinent previous echo findings (9/2021 MML): Mild LVE, moderate systolic dysfunction, mild to moderate LAE. LV: 5.3/5.4, LA: 3.67, FS: 17%.

ECHOCARDIOGRAM FINDINGS

2D, m-mode, color flow and doppler imaging is available. No significant left ventricular dilation (LVIDDn: 1.56, LVIDSn: 1.1) with mildly decreased systolic function. Minimal left atrial enlargement. The mitral valve appears mildly thickened, with no obvious prolapse into the left atrial lumen. No mitral regurgitation. The tricuspid valve appears normal in form and function. No right atrial or ventricular dilation. No tricuspid regurgitation. The aortic valve is normal in morphology and mobility. No subvalvular ridge present. Mildly elevated LVOT and RVOT velocity. No aortic insufficiency. Normal pulmonic valve with no pulmonic insufficiency seen. No pericardial or pleural effusion noted. No obvious cardiac tumors.

CARDIAC CHART

CANINE CARDIAC PARAMETERS	MR VMAX (m/s)	TR VMAX (m/s)	LA/AO (Boon method)	LA/AO (Heart Base; Swe)	FS (%)	EF (%)	EPSS (cm)
NORMAL PARAMETER	4.5-5.5	<2.7	1.3	<1.6	28-40	40-100	<0.6
PATIENT	NA	NA	NM	1.4	23	42	NM
CANINE CARDIAC PARAMETERS	HR (BPM)	AV VMAX (m/s)	PV MAX (m/s)	BODY WEIGHT (kg)	LA 2D short axis Base view (cm)	LVIDd Avg; 2D and m-mode short axis (cm)	LVIDs Avg; 2D and m-mode short axis (cm)
NORMAL PARAMETER	50-100	0.7-1.7	0.7-1.6	BELOW	BELOW	BELOW	BELOW
PATIENT	140	2.0	2.8	42.0	3.5	4.7	3.6
*Normal chamber parameters expressed as a mean value (SD)				3	1.27 (5.3)	2.46 (2.46)	1.36 (5.5)
BODY WEIGHT DEPENDENT PARAMETERS				5	1.40 (4.5)	2.74 (5.2)	1.60 (4.7)
<i>*Note: All measurements based upon multi-modal images and methods. An average value is reported.</i>				10	1.50 (3.8)	3.27 (3.5)	2.06 (3.1)
				15	1.83 (2.0)	3.71 (2.4)	2.43 (2.1)
				20	2.02 (1.9)	4.14 (2.2)	2.80 (2.0)
				25	2.18 (2.4)	4.48 (2.9)	3.10 (2.5)
				30	2.33 (3.3)	4.83 (3.9)	3.39 (3.4)
				35	2.48 (4.3)	5.17 (5.0)	3.69 (4.5)
				40	2.62 (5.2)	5.48 (6.1)	3.96 (5.4)
				50	2.88 (7.1)	6.07 (8.3)	4.46 (7.4)

INTERPRETATION OF THE FINDINGS & FURTHER RECOMMENDATIONS

Compared to the prior study there is evidence of mild improvement, likely due to Pimobendan therapy. The LV dimensions have essentially normalized, and the function improved. Additionally, the LA is decreased in size indicating low risk for complication at this time. Mildly increased flow velocity through both great vessels is noted, which was not previously documented. Baseline lab



PATIENT

Rookie Morrissey

work is recommended if not recently performed as a possible cause of this finding. No additional issues are identified.

SPECIES

Canine

Given these findings, continue the current medication regimen as prescribed. Continued follow up for the arrhythmia should be dictated by the holter monitor results as previously discussed. Prognosis remains guarded long-term with risk for progression to CHF, malignant arrhythmias and/or sudden death in the future. That being said, any improvement is certainly a good sign.

BREED

Doberman Pinscher

Monitor for development of a cough, labored breathing, exercise intolerance or collapse episodes in the future. Monitoring of sleeping breathing rates at home is recommended to screen for progression in the future. Mild activity restriction is advised. Omega fatty acid supplementation and mild salt restriction may be of some long-term benefit.

SEX

Male Neutered

The reported blood pressures are too variable to interpret. Ideally obtain serial measurements in a controlled, low stress environment and continue until the readings plateau within 5mmHg of variability for 3+ readings.

AGE

9 years

Anesthetic risk is considered mildly elevated if needed. Cardiac protective drug choices (opioid/benzodiazepine premedication, propofol or alfaxalone induction, isoflurane gas) are recommended. Pre-oxygenate for 5-10 minutes prior to induction. Monitor for arrhythmias, hypotension, and hypoxia both intra and post-operatively and intervene as necessary. Mild IV fluid restriction is recommended to avoid fluid overload. Avoid heart rate stimulating drugs such as atropine unless clinically indicated. This does not take into account the VPCs which again should be dictated by the holter monitor results.

WEIGHT

42kgs

INTERPRETED BY

Maggie Machen Lamy,
DVM, DACVIM
(Cardiology)

PLAN

Continue Pimobendan as prescribed. Baseline lab work is recommended as discussed.

IMAGING PERFORMED BY

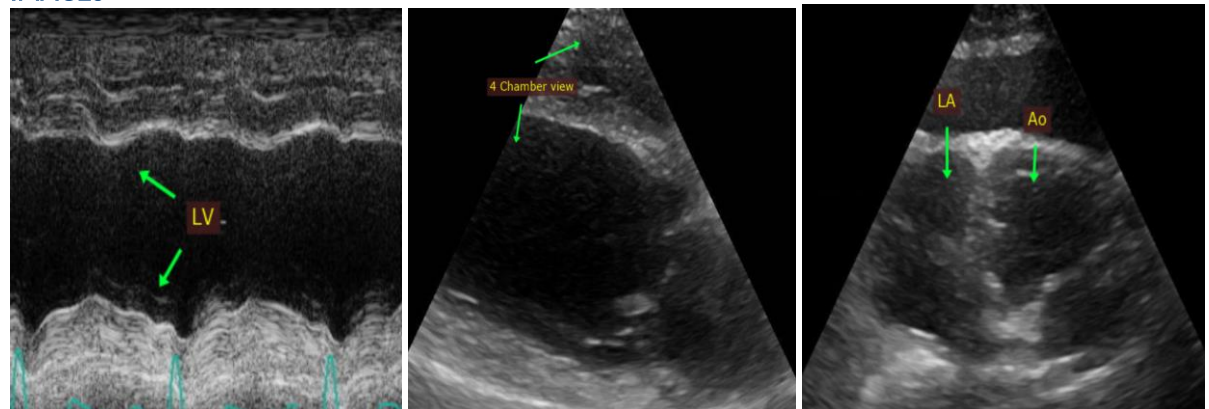
Nigel Gumley, DVM

A recheck echocardiogram is recommended in 6-8 months to assess for progression, sooner if clinical signs arise.

HOSPITAL NAME

Cedarview Animal
Hospital

IMAGES



REFERRING VET

Dr. Gumley

INVOICE

22313

DATE

12/7/21



PATIENT

Rookie Morrissey

The information and recommendations provided are based on the images presented by the referring veterinarian. No evaluation can be communicated regarding pathology that was not visible in the image/video clips provided.

SPECIES

Canine

Thank you for this referral. This report was generated using transcription software, and minor dictation errors may be present. If the clinical or image interpretation does not parallel your findings or if I can be of any further assistance, please contact me.

BREED

Doberman Pinscher

Maggie Machen Lamy, DVM
Diplomate of the American College of Veterinary Internal Medicine (Cardiology)
info@sonopath.com

SEX

Male Neutered

AGE

9 years

WEIGHT

42kgs

INTERPRETED BY

Maggie Machen Lamy,
DVM, DACVIM
(Cardiology)

**IMAGING
PERFORMED BY**

Nigel Gumley, DVM

HOSPITAL NAME

Cedarview Animal
Hospital

REFERRING VET

Dr. Gumley

INVOICE

22313

DATE

12/7/21